



## European foulbrood EFB

**Causative agent:** *Melissococcus plutonius*

**Common name:** European foulbrood

**Acronym:** EFB

EFB is a common disease of honeybee brood. It shows low prevalence in most EU countries, with a few regional exceptions where the disease is problematic.

In the EU, EFB is a disease for which national programmes may be recognized under the COUNCIL DIRECTIVE 92/65/EEC.

### Damage in colonies:

EFB is a brood disease caused by the Gram-positive bacterium *Melissococcus plutonius*. The honeybee larvae usually die from the infection when they are 4 to 5 days old, mainly before capping, but larvae can die in all stages. Adult bees can be carriers of the bacterium but no detrimental effect on adults is known. Diseased colonies may recover, but occasionally most of the brood becomes infected leading to the weakening and death of the colony. The damages from the disease seem to vary radically in different areas/countries.

### Biological cycle

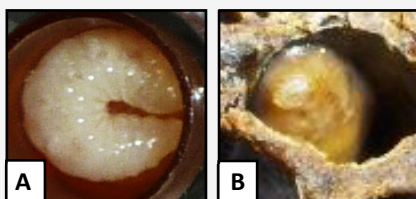
Bacterial cells of *M. plutonius* are ingested by the larvae, generally younger than 48h, with contaminated food and multiply in the midgut of the honeybee larvae. Diseased larvae are sometimes removed from the colony by nurse bees. Larvae that die from the infection may become invaded by secondary agents present in the hive such as *Paenibacillus alvei*, *Enterococcus faecalis* and *Brevibacillus laterosporus*. Some larvae die after capping and fail to pupate but discharge their faecal deposits containing infective cells of *M. plutonius*. Others manage to pupate and develop into adults leaving infective material behind.

Although *M. plutonius* is a non-spore forming bacterium it can survive under scarce conditions and remain infective possibly for several years on wax. However, it is much less resistant to disinfection than spore-producing bacteria like *Paenibacillus larvae*, the causative agent of American foulbrood.

### Suspicion criteria / consequences for the colony


#### Clinical signs:

- Patchy/spotty brood pattern (mosaic brood).
- Sunken and perforated capping.
- Color change of the infected larvae: from pearly white to pale yellow, often accompanied by a loss in segmentation (**Fig. 1 and Fig. 2**).
- Further color changes of the infected larvae to brown and grayish black sometimes leaving a dark brown scale (**Fig. 2**). The scale can easily be removed from the cells (unlike the scale resulting from American foulbrood).
- Dead larvae mostly in uncapped cells (open brood) but sometimes in capped cells (**Fig. 2**).
- Dead coiled larvae may look transparent with their tracheal system visible.
- Dead larvae malpositioned in the cell (twisted around the walls or stretched out lengthways – **Fig. 2**).
- The dead brood sometimes gives off a foul or sour smell.



**Fig. 1:** Healthy (A) and diseased (B) larva.

©Anses.




**Fig. 2:** Brood displaying diseased larvae with clinical signs of EFB. Arrows show examples of infected larvae or scale. ©Anses.

### How to check your hive:

A diagnose based only on visual inspection for signs of disease is unreliable. Laboratory confirmation is necessary. Check:

- every frame with brood individually.
- the brood, including capped brood, for the symptoms described above.
- the viscosity of the dead larvae using the match stick test for differential diagnosis with AFB. Unlike the glue-like thread typical for AFB, the remains of an EFB-affected larva rarely produce any “thread”. In case a “thread” is formed it should be shorter than 1 cm (**Fig. 3**).



**Fig. 3:** Match stick test differentiating the EFB (A) to the AFB (B). ©Anses.

## Prevention/Treatment

### The focus should be on the prevention of the disease by:

- Applying good beekeeping practices, a good *Varroa* control and prophylaxis.
- Using caution when introducing bees (e.g. buying nuclei, catching swarms), bee related products and material of unknown origin.
- Preventing robbery.
- Inspecting your colonies frequently particularly the brood.
- Renewing your wax foundation regularly. One third of your wax should be replaced yearly.
- Ensuring that there is always enough food in the colony. Feed when necessary.

### In case of an outbreak:

- Eliminate severely affected colonies with clinical signs. There are several eradication strategies, here follows an example:
  - ✓ Hermetically seal the hive entrance and other openings in the evening when all bees are inside.
  - ✓ Burn a sulfur band until all the bees are dead.
  - ✓ Remove the frames with caution.
  - ✓ Wood material can be washed with hot water and 3-5% caustic soda (sodium hydroxide) and disinfected by scorching with a blowtorch.
  - ✓ Pack dead bees and infected hive material to ensure that bees have no access and annihilate as soon as possible ideally in an incinerator.
- Affected colonies that seem to be curable may be treated by the shook swarm method, where all the combs, including the brood are destroyed and only the adult honey bees are kept alive. Then a regular specific inspection of treated colonies should be carried out for an early detection of an eventual new outbreak.
- Disinfect material that has been in contact with diseased colonies (e.g. hive tool).
- Destroy weak colonies (they are more susceptible to disease).

## What to do with suspicious cases?

EFB is not a notifiable disease at the EU level and causes minor or no problem in some areas. Control measures are not mandatory but national programmes may be recognized in some member states under the European council directive 92/65/EEC.

### Measures to be implemented in case of European foulbrood in Switzerland:

European foulbrood (EFB) is a notifiable disease in Switzerland. Outbreaks or suspected cases of this epizootic disease must be reported to the bee inspector of the canton in question. Pursuant to the technical guidelines laid down by the Federal Food Safety and Veterinary Office (FSVO), the inspector orders the sanitation measures to be taken, and monitors the hives to prevent the propagation and re-emergence of cases. Because of the strong current prevalence of EFB in Switzerland, the relevant legislation is drastic: colonies exhibiting clinical symptoms must be destroyed. The cantonal veterinary orders the implementation of a 1-km exclusion zone around the contaminated apiary in which all movement of bee colonies or beekeeping materials is prohibited. All colonies within this perimeter must be inspected by the bee inspector.